

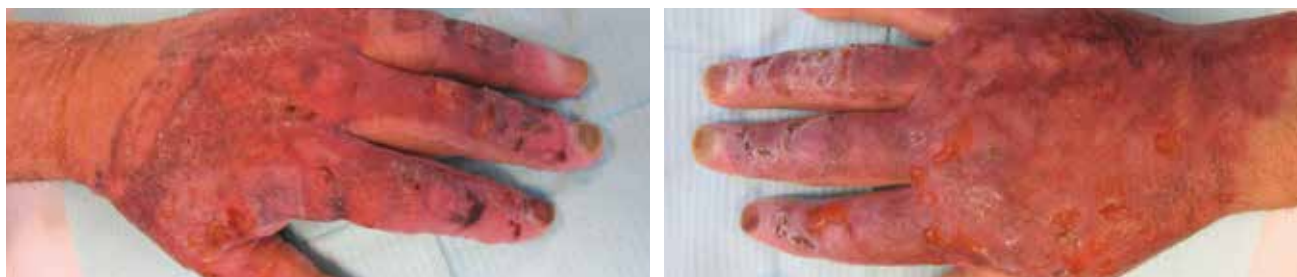
Case ALHYDRAN:

Burn caused by chemical explosion

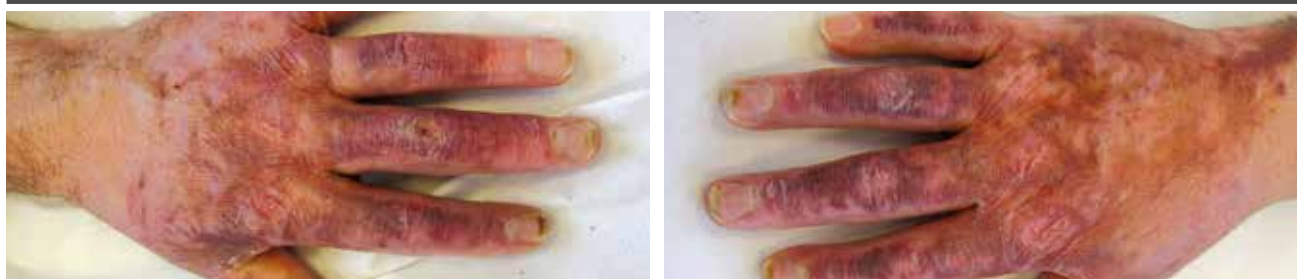1. Case study description

patient age	58 years
gender	male
cause	burn scar after explosion
treatment to wound closure	Flamazine and daily dressing change
therapy after care	ALHYDRAN, pressure gloves, scar therapy by skin therapist , endermotherapy

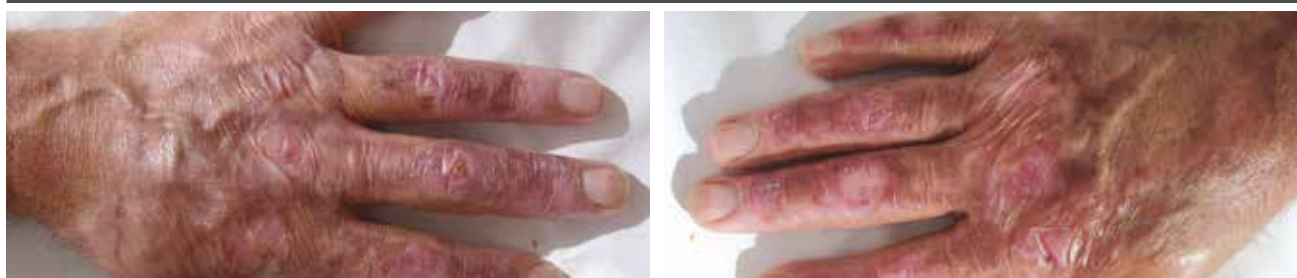2. Evolution of the skin



Start ALHYDRAN



After 3 months of ALHYDRAN therapy



After 6 months of ALHYDRAN therapy

3. Conclusions medical team

- Fast healing
- Improved restoration skin hydration
- Visibly improved supple skin
- Reduction squamae, ie. skin particles

4. Patient experience

- Skin has stopped itching
- Improved flexibility of the skin
- Reduced contractions
- Easy to apply

Case study: Ms J.M. de Graaf and Ms C.T.M. Rijkenberg, Practice Skin Therapists, Oosterbeek, the Netherlands